

Transscleral Diode Laser Cyclophotocoagulation for Refractory Glaucoma

Munira Shakir, Syeda Aisha Bokhari, Shakir Zafar, Zeeshan Kamil, Syed Fawad Rizvi

Pak J Ophthalmol 2012, Vol. 28 No. 1

See end of article for authors affiliations

Correspondence to:
Dr. Munira Shakir
Consultant Ophthalmologist
LRBT Free Base Eye
Hospital Karachi
Korangi 2½, Karachi

Purpose: To assess the efficacy of contact transscleral cyclophotocoagulation for refractory glaucoma.

Material and Methods: The study was conducted in L.R.B.T Free Base Eye Hospital from January 2008 to December 2010. All patients included in the study were diagnosed with refractory glaucoma with uncontrolled intraocular pressure on medical treatment. The study included 32 eyes of 30 patients who underwent transscleral diode laser cyclophotocoagulation (TSDLCPC) therapy. Mean follow up was 21 months. Outcome measures were intraocular pressure control and assessment of visual acuity and complications.

Results: The study included 32 eyes of 30 patients with refractory glaucoma who were treated with transscleral diode laser cyclophotocoagulation. There was significant decrease in intraocular pressure from 52.2 to 18.4 mmHg, with mean percentage reduction of 64.7%. Visual acuity remained stable in 28 (87.5%) eyes, improved in 3 (9.37%) eyes and deteriorated in 1 (3.12%) eye. Complications included early post procedure pain in 6 (26.6%) cases, moderate uveitis in 2 (6.6%) cases, hypotony in 4 (12.5%) cases, epithelial defect in 1 (3.12%) case and hyphema in 1 (3.12%) case. Re-treatment was required in 10 (31.25%) patients, which included 6 (20.25%) eyes with neovascular glaucoma, 2 (6.25%) eyes with silicone oil and 2 (6.25%) eyes with post-traumatic glaucoma.

Conclusion: Transscleral diode laser cyclophotocoagulation is a safe and effective procedure for patients with refractory glaucoma, although re-treatment sessions may be required.

One of the leading causes of irreversible blindness worldwide is glaucoma¹. When intraocular pressure (IOP) remains uncontrolled despite medication, surgical intervention may be required to preserve optic nerve function². With the advent of diode laser technology, management of uncontrolled intraocular pressure in advanced glaucomatous disease is being carried out by employing cycloablative therapy³. Cycloablation lowers intraocular pressure by thermal destruction of ciliary body epithelium and stroma^{4,5} coagulative necrosis with moderate reduction in vascularity⁶. Transscleral diode laser cyclophotocoagulation (TSDLCP) has been shown to be a safe and effective modality as compared to other cyclophotocoagulative

methods and cyclocryotherapy, which pose a significant risk of hypotony and phthisis due to excessive ablation of the ciliary body^{7,8}.

The type of laser to be used for transcleral cyclophotocoagulation is based on its scleral transmission. Transmission through the sclera increases at long wavelength⁹. Therefore, the most commonly used lasers are 810 nm diode and 1064 nm Neodymium: YAG^{10,11}. TSDLCP is divided into "contact" in which the probe is placed directly over the conjunctiva and sclera and "non-contact" in which the energy is directed towards the sclera and conjunctiva at a slit lamp in conjunction with a lens which helps to minimize conjunctival burns¹². The scleral transmission with contact application with the

810 nm diode laser and the 1064 nm Nd: YAg laser is around 60%¹³. Parameters such as pulse power and duration, total energy delivered per eye, total number of burns per session and sparing or not sparing a portion of the circumference treated with cyclodiode have been evaluated but with varying and contradictory results^{14,15}. In addition, the age of the patient, cardiovascular status, history of diabetes, past surgical and cycloablative history, trabecular outflow status and response to ocular hypotensive medications must be evaluated to estimate the likely ciliary body function. Thickened sclera may result in treatment failure, whereas; thinning of the sclera may require a reduced laser dose³. The outcome of cyclodiode therapy is, therefore, unpredictable and multiple treatments may be required to achieve the desired intraocular pressure level¹⁶.

The current study was carried out to evaluate the efficacy of transscleral diode laser cyclophotocoagulation in achieving intraocular pressure control and thereby, relieving pain of patients with refractory glaucoma.

MATERIAL AND METHODS

The study was conducted in the outpatient department of L.R.B.T Free Base Eye Hospital from January 2008 to December 2010. After informed consent, 32 eyes of 30 patients were selected for the study. Out of which 18 (56.25%) were males and 12 (37.5%) were females. Age ranged between 15 to 65 years. Inclusion criteria included all patients diagnosed with refractory glaucoma (refractory glaucoma was defined as intraocular pressure > 21 mm Hg on maximal tolerated medical therapy with or without previous surgical intervention), patients with best-corrected visual acuity \leq 6/36 on snellen chart testing and elevated intraocular pressure, patients with painful blind eye and patients whose general condition precludes invasive surgical procedures. Exclusion criteria included patients < 15 years of age, patients with thin sclera or scleral atrophy, patients who had undergone previous transscleral cyclophotocoagulation and patients with a follow up of less than 3 months. Complete data regarding patient demographics, pre and post procedure intraocular pressure, visual acuity, anti-glaucoma medications and complications was recorded. Complete ocular examination, including adenexa, anterior segment with special emphasis on iris for signs of neovascularization, pupillary light reflex, posterior segment examination including the state of the

vitreous, retina, macula and optic disc, intraocular pressure measurement with goldmann applanation tonometer and gonioscopy. The different etiologies of refractory glaucoma were as follows: 11 out of 32 (34.37%) eyes had neovascular glaucoma (NVG), 8 out of 32 (25%) patients had painful blind eye secondary to complicated cataract surgery, 5 out of 32 (15.62%) eyes had refractory glaucoma despite filtration surgery, 3 out of 32 (9.37%) were silicone filled eyes, 2 out of 32 (6.25%) eyes had post-traumatic glaucoma with scarring, 2 out of 32 (6.25%) patients were recruited because they were medically unfit for surgical procedure and 1 out of 32 (3.12%) eye had uveitic glaucoma.

Transscleral diode laser cyclophotocoagulation was performed with OculightSx with semiconductor diode laser system (810 nm wavelength) and a G-probe after administering retrobulbar or peribulbar anesthesia. Duration was set at 1500 – 2000 ms (1.5 – 2 sec) and the initial power setting was 1500 – 1750 MW. Power was increased in 250 MW increments till a “popping” sound was heard which indicates boiling of intracellular fluid with tissue disruption and can lead to increased post operative inflammation. The fiber optic tip of the G-probe was placed 1 – 1.5 mm from the limbus. The probe was held parallel to the visual axis and the foot plate was placed firmly against the sclera. Initially 16 – 20 burns were given in the superior 180° with resultant energy of 3.5 J/shot. Horizontal meridian (i.e. 3 and 9 o'clock positions) were spared to avoid the long ciliary nerves. If further treatment sessions were required then the remaining 180° was treated. Post-procedure steroid-antibiotic eye drops and oral painkillers were prescribed. Anti-glaucoma medications were continued for a week. Patients were followed the next day, after 1 week, weekly for 1 month and thereafter monthly for 2 years.

Success was defined as a final intraocular pressure < 22 mm Hg or a decrease in intraocular pressure of > 30% from the pre-operative baseline value. Improvement in visual acuity was defined as gain in \geq 1 snellen line. Deterioration in visual acuity was defined as loss of \geq 1 snellen line.

RESULT

A total of 32 eyes of 30 patients with refractory glaucoma were treated with transscleral diode laser cyclophotocoagulation. There were 18 (56.25%) males and 12 (37.5%) females with age ranging from 15-65 years. Mean follow up was 21 months. Treatment

outcomes were assessed on the following 3 parameters:

CONTROL OF INTRAOCULAR PRESSURE: Pre-procedure intraocular pressure was 31-40 mm Hg in 7 (21.8%) eyes; 44 - 50 mm Hg in 9 (28.12%) eyes; 51 - 60 in 12 (37.5%) eyes and 61 - 70 mm Hg in 4 (12.5%) eyes. Post-procedure intraocular pressure at final follow up was 10 - 14 mm Hg in 8 (25%) eyes; 15 - 18 mm Hg in 10 (31.25%) eyes; 19-22 in 10 (31.25%) eyes and 38-50 mm Hg in 4 (12.5%) eyes. Mean pre-operative intraocular pressure was 52.2 mm Hg whereas; mean post-operative intraocular pressure was 18.4 mm Hg with a percentage reduction of 64.7%. Success rate (IOP between 5 - 21 mm Hg) was noted in 87.5% patients at the last follow up.

VISUAL ACUITY: Pre-procedure visual acuity was NPL in 12 (37.5%) out of 32 eyes, PL in 9 (28.12%) out of 32 eyes, counting finger in 7(21.8%) out of 32 eyes, 6/60 in 3 (9.37%) out of 32 eyes and 6/36 in 1 (3.12%) out of 32 eye. Post-procedure visual acuity was NPL in 15 (46.8%) out of 32 eyes, PL in 7 (21.8%) out of 32 eyes, counting finger in 4 (12.5%) out of 32 eyes, 6/60 in 5 (15.6%) out of 32 eye and 6/36 in 1 (3.12%) out of 32 eye. Visual acuity remained stable in 24 (75%) out of 32 eyes, improved in 3 (9.37%) out of 32 eyes and worsened in 5 (15.62%) out of 32 eyes. Deterioration of vision was observed in 2 (6.25%) patients with NVG, 1 (3.12%) eye which was silicone oil filled, 1 (3.12%) eye with uveitic glaucoma and 1 (3.12%) eye with post-traumatic glaucoma with scarring.

COMPLICATIONS: Early post-procedure pain was seen in 6 (20.25%) out of 32 eyes, hypotony in 4 (12.5%) out of 32 eyes. 2 (50%) out of 4 eyes with hypotony ended up in phthisisbulbi, whereas the remaining 2 (50%) out of 4 eyes regained intraocular pressure ≥ 8 with conservative treatment after 6 weeks; moderate uveitis was observed in 2 (6.6%) out of 32 eyes, epithelial defect in 1 (3.12%) out of 32 eye and hyphema in 1 (3.12%) out of 32 eye. Hyphema appeared in one patient with neovascular glaucoma.

Re-treatment was done in 10 (31.25%) of 32 eyes after 8 weeks, which included 6 (20.25%) eyes with NVG, 2 (6.25%) eyes with silicone oil and 2 (6.25%) eyes with post-traumatic glaucoma.

DISCUSSION

Cyclodiode coagulation has proved to be an effective treatment modality for advanced and long-standing refractory glaucoma^{17,18}. It acts by decreasing aqueous production regardless of trabecular function¹⁹. In the

present study, the mean pre-procedure intraocular pressure was 52.2 mm Hg which reduced to 18.4 mm Hg after cyclodiode coagulation, giving a percentage intraocular pressure reduction of 64.7%. This is in accordance with other studies which have demonstrated a decrease of 20 - 60% in mean intraocular pressure^{3,20}. The rate of success in this study was defined as a final intraocular pressure < 21 mm Hg or a decrease in intraocular pressure by 30% from baseline intraocular pressure. Transscleral diode laser cyclophotocoagulation in this study achieved a success rate of 87.5%. Results in literature vary from 48% to 92%²¹⁻²³. This success rate seemed to be related to higher power settings and increased number of treatments²⁰. Murphy et al, in their study evaluated the relation between total energy delivered during cyclodiode therapy for refractory glaucoma and a reduction in intraocular pressure over a range of laser energies, but they did not find any linear dose-response relation which would help predict the outcome of cyclodiode therapy²⁴. This finding is supported by previous reports^{25,26}. In the current study visual acuity remained stable in 75% of cases, improved in 9.37% and deteriorated in 15.62% cases. Similar findings were found in the study conducted by Murphy et al. In their study visual acuity remained stable in 74.6% of the patients, improved in 5.3% and decreased in 19.8% of the patients²⁴. However, in another study, 17 % eyes maintained stability, 29.1% exhibited improvement and 31.6% suffered deterioration²⁷. The most serious side effects of cyclodiode therapy are hypotony and phthisis. It has been postulated that variables such as method of laser delivery, treatment parameters and follow up period might contribute to hypotony. Also, high intraocular pressure before the procedure may result in ciliary ischemia which may induce ciliary body shutdown following cyclophotocoagulation. Therefore one approach is to keep the initial setting of laser energy at a low level and to give multiple treatment sessions at 6 - 8 weeks, thus minimizing the risk of hypotony¹⁹. The rate of occurrence of hypotony varies widely in literature from 0 - 18%²⁴. In the present study hypotony was seen in 12.5% of cases. Other side effects observed were early postoperative pain in 20.25% of the eyes. Moderate uveitis was seen in 6.6% of the eyes. Mehmood et al also reported uveitis in 7% patients²⁰. Hyphema was encountered in one case (3.12%) that had neovascular glaucoma. Other investigators also reported hyphema in neovascular glaucoma patients who underwent cyclodiode therapy²⁸. Re-treatment rate in the current study was

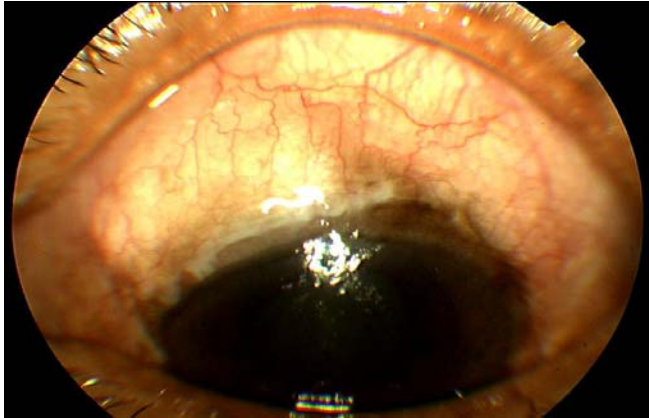

Fig. 1: Glaucoma refractory to trabeculectomy

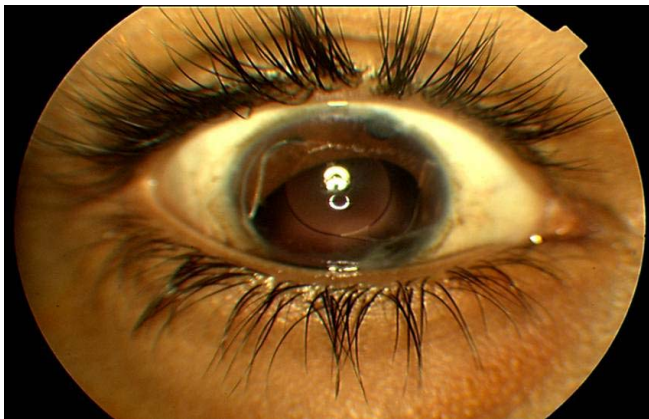


Fig. 2: Traumatic glaucoma with surface scarring

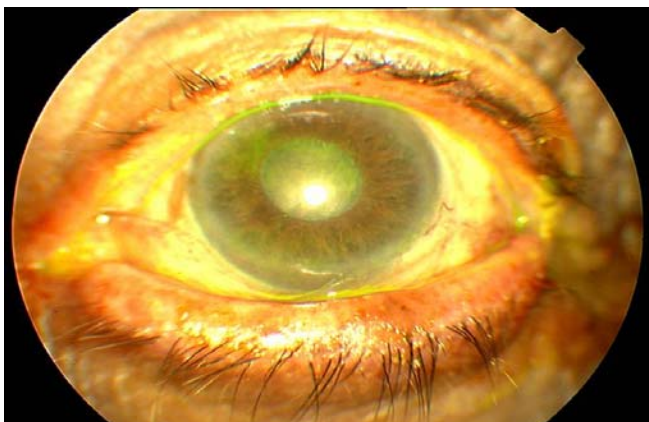


Fig. 3: Painful blind eye

31.25%. Other studies show a re-treatment rate ranging from 22% to 45.8%^{16,24,29}. Re-treatment was done in 20.25% eyes with neovascular glaucoma, 6.25% eyes with silicone oil, and 6.25% eyes with traumatic glaucoma. Other studies reveal that patients

with neovascular glaucoma, post-traumatic glaucoma and post-vitreoretinal surgery glaucoma tend to need higher number of repeated treatment sessions^{16,24}.

CONCLUSION

To summarize, the current study showed that diode laser cyclophotocoagulation is an effective treatment option for refractory glaucoma of all etiologies. However, prospective trials are required to assess safety and long-term outcome.

Author’s affiliation

Dr. Munira Shakir
 Consultant Ophthalmologist
 LRBT Free Bias Eye Hospital Karachi
 Korangi 2 ½ Karachi

Dr. Syeda Aisha Bokhari
 Associate Ophthalmologist
 LRBT Free Bias Eye Hospital Karachi
 Korangi 2 ½ Karachi

Dr. Shakir Zafar
 Consultant Ophthalmologist
 LRBT Free Bias Eye Hospital Karachi
 Korangi 2 ½, Karachi

Dr. Zeeshan Kamil
 Associate Ophthalmologist
 LRBT Free Bias Eye Hospital Karachi
 Korangi 2½, Karachi

Dr. Syed Fawad Rizvi
 Chief Consultant Ophthalmologist
 LRBT Free Bias Eye Hospital Karachi
 Korangi 2½, Karachi

REFERENCE

1. **Quigley HA, Bromman AT.** The number of people with glaucoma worldwide in 2010 and 2020. *Br J Ophthalmol.* 2006; 3: 262-7.
2. **Lai JS, Tham CC, Lam DS et al.** surgical management of chronic closed angle glaucoma. *Asian Pac J Ophthalmol.* 2003; 15: 5-10.
3. **Walland MJ.** Diode laser cyclophotocoagulation: Long-term follow up of a standardized treatment protocol. *Clin Exp Ophthalmol.* 2000; 28: 263-7.
4. **Feldmann RM, El-Harazi SM, LoRusso FJ et al.** Histopathological findings following contact trans scleral semiconductor diode laser cyclophotocoagulation in a human eye. *J Glaucoma.* 1997; 2: 139-40.
5. **Neocker RJ, Kelly T, Patterson E et al.** diode laser contact trans scleral cytophotocoagulation: getting the most from the G-probe. *Ophthalmologic surg lasers imaging.* 2004; 35: 124-30.

6. **McKelvie PA, Walland MJ.** Pathology of cyclodiode laser: a series of nine enucleated eyes. *Br J Ophthalmol.* 2001; 85: 474-6.
7. **Oguriu A, Takahashi E, Tomita G, et al.** Transscleralcyclophotocoagulation with the diode laser for neovascular glaucoma *Ophthalmologic surg Lasers.* 1998; 29: 722-7.
8. **Schumann JS, Bellows AR, Shingleton BJ.** Contact transscleral Nd: Yag laser cyclophotocoagulation. Mid-term results. *Ophthalmology.* 1992; 99: 1089-95.
9. **Vogel A, Dlugos C, Nuffer R, et al.** optical properties of human sclera, and their consequences for transscleral laser applications. *Laser Surg Med.* 1991; 11: 331-40.
10. **Schlote T, Derse M, Rassmann K, et al.** Efficacy and safety of contact transscleral diode laser cyclophotocoagulation for advanced glaucoma. *J Glaucoma.* 2001; 10: 294-301.
11. **Lin P, Wollstein G, Schuman JS.** Contact transscleral laser cyclophotocoagulation. Long-term outcome. *Ophthalmology* 2004; 111: 2137-43; Erratum in: *Ophthalmology.* 112: 446
12. **Schuman JS, Noeker RJ, Puliafito CA, et al.** Energy levels and probe placement in contact transscleral semiconductor diode laser cyclophotocoagulation in human cadaver eyes. *Arch Ophthalmol.* 1991; 109: 1534.
13. **Raivio VE, Puska PM, Immonen IJR.** Cyclophotocoagulation with the transscleral contact red 670 nm diode laser in the treatment of glaucoma. *Acta Ophthalmol.* 2008; 86: 558-64.
14. **Chang SH, Chen YC, Li CY, et al.** Contact diode laser transscleralcyclophotocoagulation for refractory glaucoma: comparison of two treatment protocols. *Can J Ophthalmol.* 2004; 39: 511-6.
15. **Noureddin BN Zein W, Haddad C, et al.** diode laser transscleralcyclophotocoagulation for refractory glaucoma: a 1-year follow up of patients treated using an aggressive protocol. *Eye.* 2006; 20: 329-35.
16. **Iliev ME, Gerber S.** Long-term outcome of transscleral diode laser cyclophotocoagulation in refractory glaucoma. *Br J Ophthalmol.* 2007; 91: 1631-5.
17. **Werner A, Vick HP, Guthoff R.** Cyto photocoagulation with diode laser. Study of long-term results. *Ophthalmology.* 1998; 95: 176-80.
18. **Threlked AB, Johnson M.** Contact transscleral diode cyclophotocoagulation in refractory glaucoma: comparison between pediatric and adult glaucomas. *Ophthalmic Surg Lasers.* 2001; 32: 100-7.
19. **Mehta R, Puthuran G, Krishnadas R, et al.** Efficacy of transscleral diode laser cyclophotocoagulation for refractory glaucoma in South Indian population. *Asian J Ophthalmol.* 2006; 8: 232-5.
20. **Mahmood K, Baig RA, Baig MJ, et al.** transscleral diode laser cyclophotocoagulation for the treatment of refractory glaucoma. *Pak J Ophthalmol.* 2007; 23: 204-8.
21. **Schlote T, Derse M, Zierhut M.** transscleral diode laser cyclophotocoagulation for the treatment of refractory glaucoma secondary to inflammatory eye disease. *Br J Ophthalmol.* 2000; 84: 999-1003.
22. **Egbert PR, Fiadoyer S, Budenz DL, et al.** diode laser transscleralcyclophotocoagulation as a primary surgical treatment for primary open angle glaucoma. *Arch Ophthalmol.* 2001; 119: 345-50.
23. **Gupta V, Agarwal HC.** Contact trans-scleral laser cyclophotocoagulation treatment for refractory glaucomas in the Indian population. *Indian J Ophthalmol.* 2000; 48: 295-300.
24. **Murphy CC, Burnett CAM, Spry PGD, et al.** A two-center study of the dose-response relation for transscleral diode laser cyclophotocoagulation in refractory glaucoma. *Br J Ophthalmol.* 2003; 87: 1252-7.
25. **Benson MT, Nelson ME.** Cyclocryotherapy : a review of cases over a ten year period. *Br J Ophthalmol.* 1990; 74: 103-5.
26. **Wong EYM, Chew PTK, Chee CKL, et al.** diode laser contact transscleralcyclophotocoagulation for refractory glaucoma in Asian patients. *Am J Ophthalmol.* 1997; 124: 797-804.
27. **Alipanahi R.** Long-term outcome of transscleral diode laser cyclophotocoagulation for refractory glaucoma. *Rawal Med J.* 2008; 33: 173-5.
28. **Tam Fam AM, Chockalingam M, Aquino M, et al.** Micropulsetransscleral diode laser cyclophotocoagulation in the treatment of refractory glaucoma.
29. **Afifi MN.** Dide laser cyclophotocoagulation. [Online] 2010 [cited 2010]; Available from: URL: <http://www.glaucoma-egypt.org/Glaucoma-news/2010-01.pdf>.